

SENSITIVITY AND FATALITY OF SALINOMYCIN TO SAUDI DROMEDARY CAMELS: A PILOT STUDY

N.A. Al-Wabel

Department of Veterinary Medicine, College of Agriculture & Veterinary Medicine,
Qassim University, P.O. Box 6622, Buraidah 51452, Saudi Arabia

ABSTRACT

Sensitivity and fatality of salinomycin to Saudi dromedary camels (*Camelus dromedarius*) was studied. The clinical symptoms and analysis of feed content pointed at salinomycin as the possible causative agent. In a small trial (n=7), we tested the effect of doses of salinomycin, 15mg/kg every second day on dromedary camels of local strain. We observed a mortality rate of 100% after just a few days of treatment and the camels showed great sensitivity to salinomycin. Clinically, camels showed signs of severe fatigue and sickness. Treatment severely affected physiological parameters of the heart rate and respiration. That was associated with a dramatic change in biochemical and enzymes level. At the post mortem analysis, we found severe tissue necrosis and severe haemorrhage. Organs that are severely damaged were the heart, kidney and liver.

Key words: Ionophores, mitochondria, salinomycin

Salinomycin is a coccidiostatic antibiotic that chemically belongs to the ionophores (Pressman and Fahim, 1982). In agriculture, it's in use as feed supplements, and growth promoting agent to ruminant and poultry (Callaway *et al*, 2003; Johansen *et al*, 2007 and Hall, 2001). Although the use of antimicrobial additives is rather a controversial issue, they are available and in use in many countries around the world (Newcombe *et al*, 1992).

An incidence of a sudden camel death was reported in the south region of the kingdom of Saudi Arabia in 2007. Thousands of camels died as a consequence of consumption of unknown contaminant in camel feed. The report of Ministry of Agriculture pointed at 3 possible causative agents including salinomycin, mycotoxin and aluminum. However, clinical symptoms observed in sick camels are in particular quite similar to toxicity observed in other animals by salinomycin. Following the footsteps of salinomycin toxicity incidence in different animals, there were some alarming observations in the literature regarding the use of salinomycin. Evidence accumulating that salinomycin has different pharmacodynamic and probably pharmacokinetic profile in different animal species (Lagas *et al*, 2008).

Available literature does show studies on toxicity of salinomycin in camels. This pilot trial was designed to study the effect of salinomycin toxicity in camels.

Materials and Methods

Animals

Seven male camels weighing 325–500 kg (BW) aged 5–12 years were used in the pilot trial. All animals were examined at Qassim University Veterinary Hospital and considered clinically healthy, and had no previous drug treatment. The animals were kept in ambient conditions, fed on alfalfa and had free access to food and water. The protocol used in this study was approved by the ethical committee of the University of Qassim.

Experimental design

All camels were subjected to clinical examination at 10 am and the following parameters were recorded for several days before the first dose of salinomycin: core body temperature, ruminal contractility and respiration and heart rate. To observe any difference in age response to salinomycin camels were divided into small groups as follow: Group A: 3 camels age 5- 8 years, Group B: 2 camels age 10 years, and group C: 2 camels age 12.

Drug administration

All biochemical tests were measured once before the first dose of salinomycin and all camels with abnormal biochemical reading were excluded from the study. Thereafter, camels received an oral dose of 15mg/kg BW every second day.

SEND REPRINT REQUEST TO N.A. AL-WABEL [email: hasmoua@homail.com](mailto:hasmoua@homail.com)

Haematological test

Before salinomycin dosing, blood samples were collected in heparinised tubes from all camels for haematological analysis on day 1, day 3, day 6 and day 10 of the treatment. The following tests were measured: haemoglobin (Hb), red blood cell count (RBCs), packed cell volume PCV, total white blood count (Total WBCs count) and differential WBCs count. These parameters were determined by the Abbott Cell Dyn® 3500 (Abbott Diagnostic Division, California, USA) which was previously calibrated for blood of sheep, goats and camels.

Biochemical analysis

Another set of blood samples were collected to determine the activities of liver, muscle, and kidney enzymes and that includes: Aspartate aminotransferase (AST), Alanine aminotransferase (ALST), creatine phosphokinase (CPK) and alkaline phosphatase (ALP)., glucose, creatinine, urea, potassium (K) were determined by commercial kits (bio-Merieux Laboratory Reagents and Products, France and kits from Nubenco Interprises INC. Paramus, New Jersey, USA). Besides, Rumen fluid was collected to examine the physical characteristics (colour, odour & consistency), chemical (PH & Methylene Blue Reduction test) and microscopic examination for protozoal activity.

Data analysis and statistics

Individual physiological parameters of each camel were plotted against measurement before treatment and in comparison to one negative control reading. Haematological and biochemical measurement results were analysed using one way ANOVA with Kruskal-Wallis test for multiple comparisons using Prism software.

Results

General clinical signs

After salinomycin treatment, an acute onset of illness and abnormal behaviour among camels were noticed. All camels became lethargic, anorexic, had loose faeces, stopped rumination, stiff-legged and reluctant to move 24 hours after ingestion of salinomycin (Fig 1A) and preferred staying in sternal recumbency.

Respiratory rate

As shown in Fig 2A, a gradual but significant change in rate of respiration $P < 0.05$ was observed for most camels starting on day 6. A higher frequency of respiratory rate of 16.67 ± 0.33 , almost double

the normal average rate of 7 ± 0.25 , was observed thereafter. A significant increase in respiration frequency was observed after day 6 (9.6 ± 0.812) and it was persistent.

Heart rate

As shown in Fig 2B, a similar increase in heart rate of the camels was observed in camels starting of day 6. Heart rate changed from negative control of 37.13 ± 0.39 to 48 ± 0.4 .

Body temperature

Core body temperature changes in camels started later than the changes in cardiac rate for most of the camels (Fig 2C). It reached significant level ($P < 0.05$) on day 8 of salinomycin treatment. The average core body temperature of camels before treatment was 35.94 ± 0.12 C° while on day 7 the average reading was 36.28 ± 0.22 C°. Maximum reading was recorded on day 11 and it was 39.1 ± 0.05 C°. Symptomatic hydration of camels was not effective in reducing body temperature. Dehydration is known to increase respiration and body temperature significantly in some animal species but not in camels (Ayoub and Saleh, 1998). Salinomycin treatment seems to elevate both.

Fatality

The fatality observed after salinomycin treatment was 100% and supportive and symptomatic treatments were found to be ineffective. It was also noted that camel survival days were correlated to camel age.

The sequence of camel death in groups was as follow: Group A: 3 camels age 5 8 yrs died on day 11, 12 after receiving 5 doses of salinomycin. Group B: 2 camels age 10 yrs. died on day 10 after 4 doses. Group D: 2 camels age 12 yrs one camel died on day 3 after one injection. The other died on day 3 post administration of one dose of salinomycin equal to 6 g.

Haematological results

Table 1 shows changes in blood count of lymphocytes, esinophils, neutrophils and PCV. It was noticed that a significant decrease in lymphocytes counts and the count was reduced to the maximum on day 10 of salinomycin treatment. On the contrary, a gradual and significant increase in eosinophils and neutrophils counts was observed from day 3 to day 10 after salinomycin treatment. A significant increase in PCV value was noticed in day 10.

Biochemical results

Salinomycin treatment has a profound effect on biochemical parameters. As shown in Fig 3A, the level



Fig 1A. Camel showing complete muscle weakness, and stiffness and reluctance to move due to acute salinomycin toxicity. The clinical signs included muscle weakness and ataxia that progressed from hind legs to shoulder and chest over 2 days period, dyspnoea, tachypnoea, tachycardia, thirst, lethargy, grunting and signs of pain. Rise in body temperature was noticed 1-2 days before death. Animal died with lesions of congestive heart failure (Fig 1B).



Fig 1B. Death within 24 - 48 hours due to administration of high dose of salinomycin.

of creatinine became triple by day 10 and unregulated from average value of 1.19 ± 0.3 to 3.1 ± 0.32 mg/dl. This significant change indicates an ongoing process of muscle degeneration.

Fig 3B shows the effects of salinomycin treatment on serum potassium level. The level of K dropped from a control value of 3.8 ± 0.09 to 3.2 ± 0.11 mmol/l ($P < 0.05$). Level of serum K dropped further on day 10 to an average of 2.6 ± 0.1 mmol/l.

As we noticed anorexia and avoidance of feeding, camels serum glucose reflect a gradual and significant decrease in serum glucose level. As

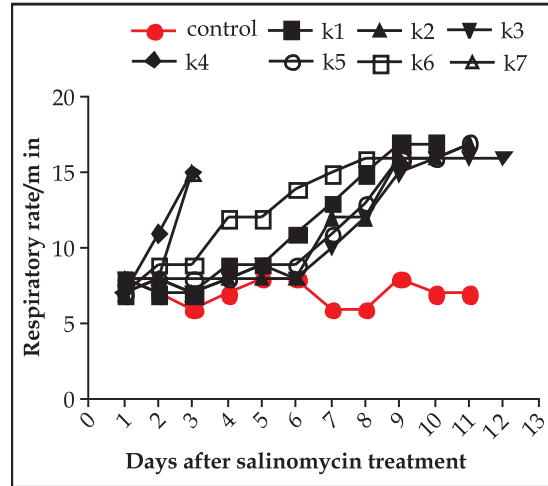


Fig 2A. Respiratory rate after treatment with salinomycin.

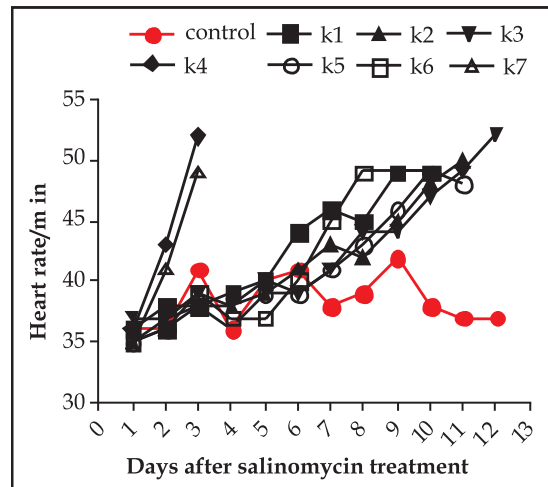


Fig 2B. Heart rate after treatment with salinomycin.

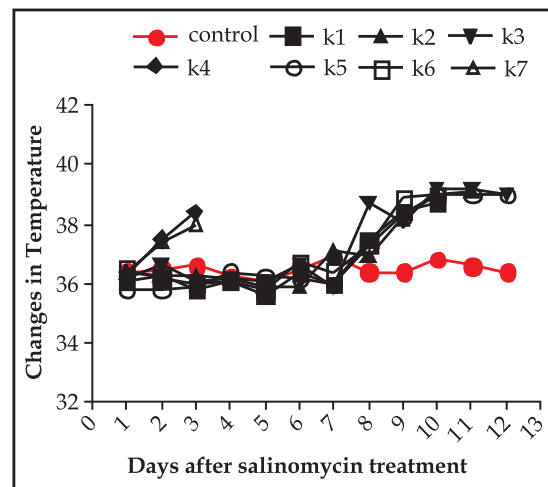


Fig 2C. Change in camel temperature after treatment with salinomycin.

Table 1. Blood count of lymphocytes, eosinophils, neutrophils and PCV.

Cells	control	day1	day3	day6	day10
Lymphocytes	55±0.28	55.86±0.40	45.13±2**	43±2.4***	35.6±1.2***
Eosinophils	3.8±0.2	3.71±0.35	8.17±1.04***	11.4±0.50***	15.4±0.4***
Neutrophils	35.25±0.4	34.88±0.39	41.14±0.4***	44±0.54***	47±1***
PCV	32.6±0.6	32.5±0.04	33.51±0.6	34.56±0.5	44.1±.5*

P< 0.05

shown in Fig 3C, the maximum drop was observed in day 10 and it reduced from an average of 66.4±1 to 29±0.6.mg/dl.

Fig 3D shows changes in urea serum level. The reduction of urea concentration was quite dramatic on day 10 of salinomycin treatment. The level dropped from an average of 13.5±0.2 to 5.66±0.4. mg/dl.

The Level of ALT enzyme changed dramatically after salinomycin as shown in Fig 4.

A gradual but significant change was observed after the very first dose. The level change gradually

from basic level of 9.3±0.1 to 34.4±11 to a maximum of 106±14 U/l on day 10.

The same response was observed in level of ALP. As shown in Fig 4B, level of ALP changed from basic level of 49.6±1.4 to 156.3±16.35U/l.

As shown in Fig 4C, the level of AST shows a substantial change in liver function. The serum level changed from an average level of 67±0.5 to 680± 125U/l. This highly significant value indicates fundamental change in a liver function and necrosis.

Necropsy findings

All camels were subjected to necropsy examinations after death. Heart examination showed signs suggestive of congestive heart failure,

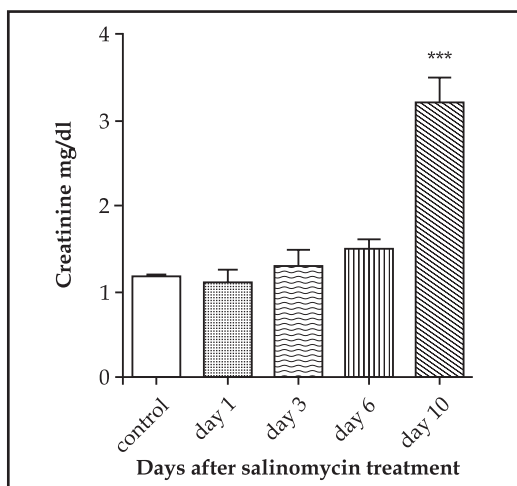


Fig 3A. Creatinine level after salinomycin treatment.

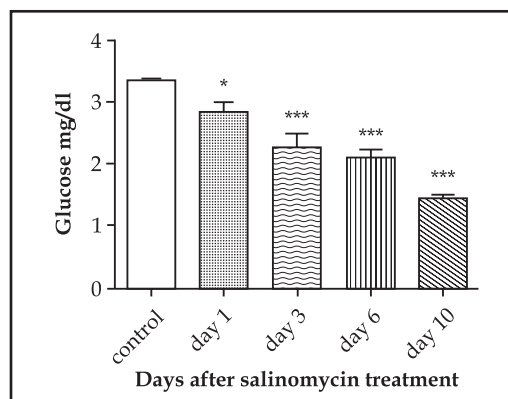


Fig 3C. Glucose level after salinomycin treatment.

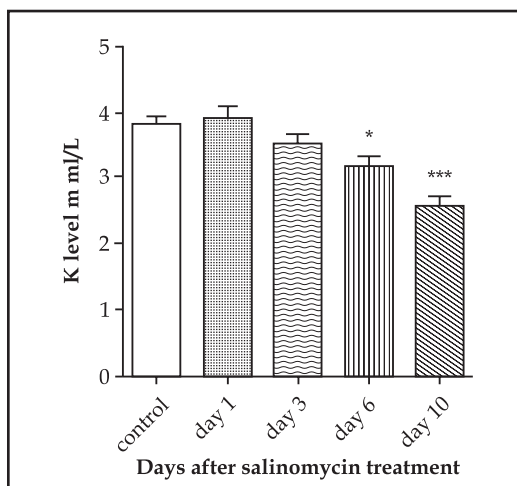


Fig 3B. Potassium level after salinomycin treatment.

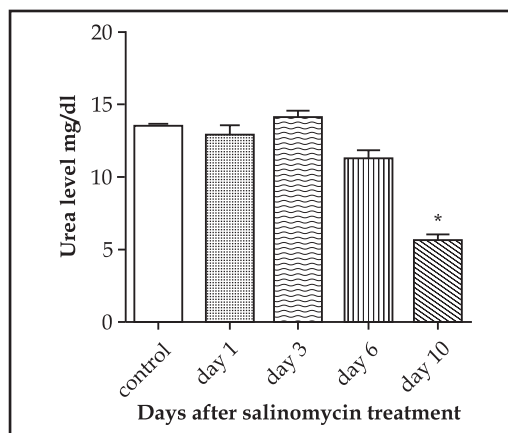


Fig 3D. Urea level after salinomycin treatment.

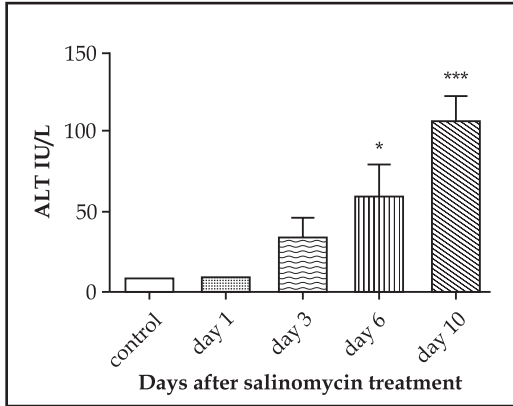


Fig 4A. ALT changes after salinomycin treatment.

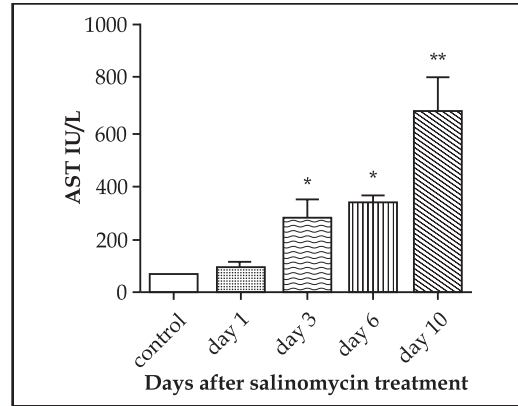


Fig 4C. AST level after salinomycin treatment.

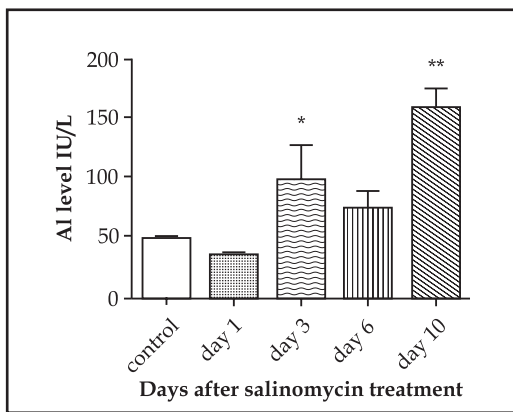


Fig 4B. AL level after salinomycin treatment.

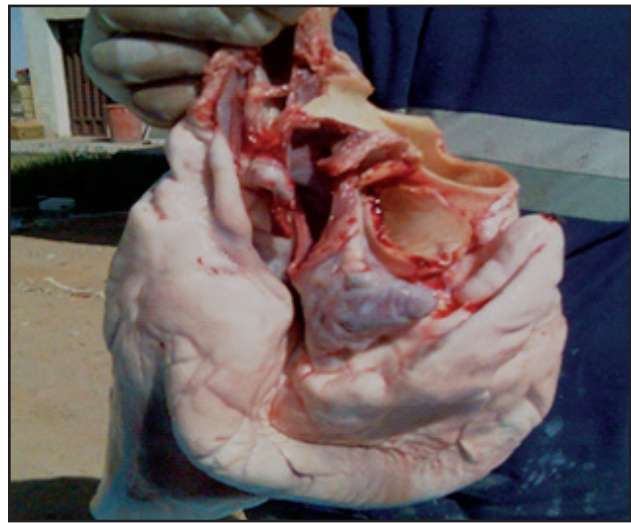


Fig 5A. Pale and flabby myocardium.

pulmonary oedema, pale and flabby myocardium (Fig 5A).

Other deleterious signs observed the presence of hydrothorax and hepatomegaly enlarged and pale kidneys (Fig 5B). The ruminal wall was hyperemic and the intestine was empty and congested. The bladders of all camels contained discoloured brownish urine. The bladder mucosa was normal. The skeletal muscles were oedematous and no visible lesions were noticed in the brain.

Histopathology

Light microscopic examination of liver sample showed multifocal areas of haemorrhage and necrosis of hepatocytes (Fig 6A).

It appears clearly that salinomycin produced severe direct cytotoxic injury to hepatocytes.

Significant damage was observed in kidney tissues. Tubular lesions appeared under examination as congested capillary, diffuse cortical and medullary haemorrhages (Fig 6B).

There were a also glomerular lesions characterised by thickening of Bowman capsule and increased cellularity of the glomeruli (Fig 6C).



Fig 5B. Enlarged and pale kidneys.

Discussion

The present study indicates that a dose of 15mg/kg of salinomycin given every other day caused severe toxicity in camels. Symptoms of toxicity

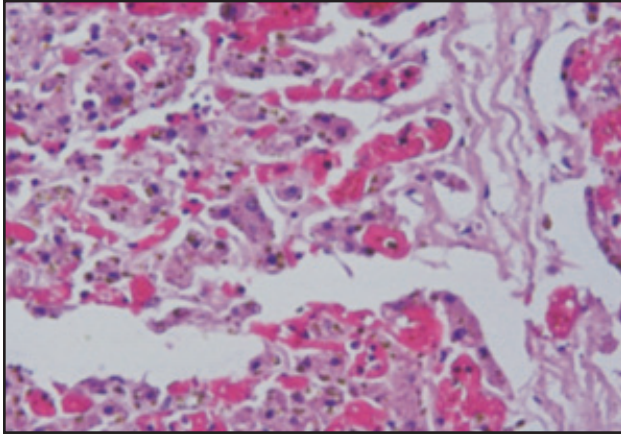


Fig 6A. Liver sample showing multifocal areas of haemorrhage and necrosis of hepatocytes.

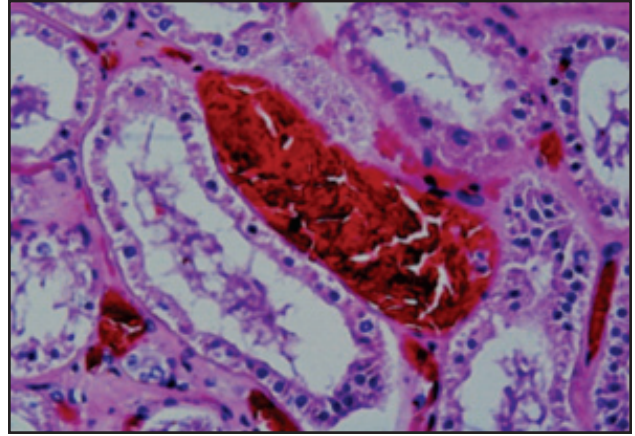


Fig 6B. Tubular lesions appear as congested capillary, diffuse cortical and medullary haemorrhages.

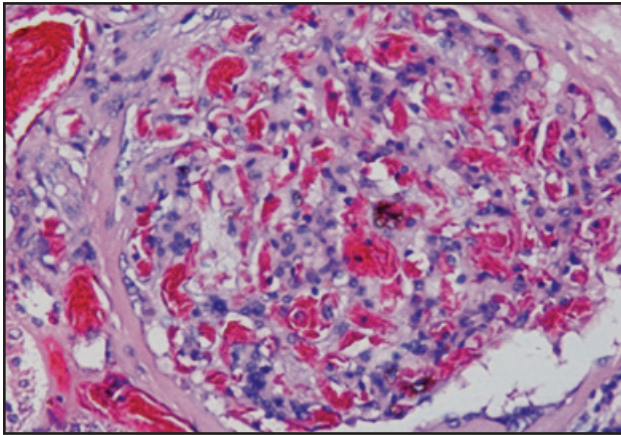


Fig 6C. Thickening of Bowman capsule and increased cellularity of the glomeruli. There was presence of large numbers of erythrocytes in the glomerular tuft and dilatation of renal tubules. Examination of intestinal specimen showed mononuclear cellular infiltration on the lamina propria, desquamation of surface epithelium and oedema of the sub mucosa (Fig 6D).

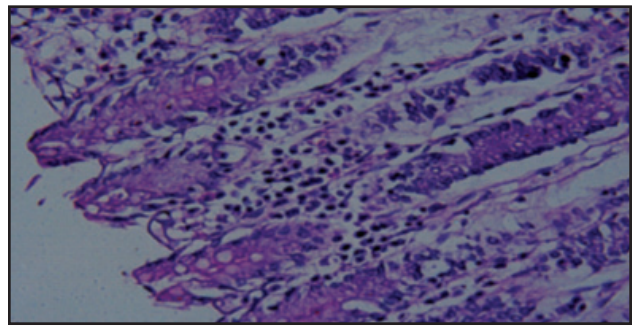


Fig 6D. Intestinal specimen showing mononuclear cellular infiltration on the lamina propria, desquamation of surface epithelium and oedema of the sub mucosa.

developed quickly and animals did not survive by symptomatic treatment. The clinical symptoms and necropsy pointed to multiple organ failure which led to death. An average cumulative dose of 36 g or an acute dose of 6 g proved to be fatal to camels. The symptoms of toxicity and biochemical findings in camels were found to be quite similar to salinomycin toxicity reported in other species; however, it was found to be more intense in camels. Heart was found to be in particular a vulnerable target in salinomycin toxicity. Necropsy showed a visibly dilated myocardium, hypertrophy and clear signs of congestive heart failure.

This finding has been observed in previous studies of ionophore toxicities (Agaoglu *et al*, 2002; Galitzer *et al*, 1986; Bastianelli *et al*, 1995; Delvi

and Sawant, 1990). The deleterious lesions were described previously as degeneration, and diffuse hypertrophy of myocardial nuclei. Interestingly, different animal species showed the same signs of cardiac toxicity and damage due to ionophores (Veet and Ferrans, 1984).

The underlying cause of myocardial damage is probably the change in mitochondrial coupling and disturbance of K, Ca and Na levels. Salinomycin is a lipid soluble ionic ionophore which has the ability to act as a vehicle for cations such as sodium, potassium and calcium (Pressman and Fahim, 1982). Hypokalaemia, per se, could produce myocardial fibrillation which leads to heart failure (Tribulova *et al*, 2000) and heart muscles are sensitive to subtle changes in ion balance (Harrison and Boyett, 1995). A change in creatinine level in salinomycin case is also an indicative of severe and direct muscular tissue damage.

As shown in Figs 4 and 5, salinomycin treatment induced substantial change in serum level of liver and kidney damage markers, AST, ALT, CPK and ALP.

In the present study severe haemorrhage and tissue necrosis were noticed in kidney and liver tissues (Fig 6B and C). Salinomycin produces massive cellular and tissue damage, the mechanism of this damage is rather a complex one. This ionophore has the ability to alter trans-membrane ion gradient and electric potentials; probably those are the core etiology of its toxicity (Pressman and Fahim, 1982).

It is a polyether organic anion in nature which has very high lipid solubility that allow salinomycin to form cation complex with K^+ and Na^+ ions and serve as a carrier for them in all body cells. Disturbance in ion balance of the mitochondria could trigger "the mitochondrial death" which involved releasing destructive free radicals and apoptotic mediators. Molecular events of mitochondrial death is believed to start by the release of mitochondrial cytochrome C which triggers the activation of caspase proteases and death of cells by apoptosis (Goldstein *et al*, 2001). In heart failure apoptotic death associated with caspase-3 and release of cytochrome C (Narula *et al*, 1999). Mechanism of necrotic cell death changes was observed in multi-organs in salinomycin however, besides disturbance in cell membrane ions required more investigation. Leaking of cellular enzyme contents observed is a very good evidence of membrane cell failures.

Most biological systems are equipped with a defense system to protect against xenobiotics harmful effect. That includes ATP-binding cassette multidrug transporters like P-glycoprotein (P-gp, ABCB1), BCRP (ABCG2), and MRP2 (ABCC2). It is an indigenous pump which helps efflux of drugs and other substrate outside the absorbing lumen site. They are located at critical sites of transportation in intestine, liver and kidney (Klappe *et al*, 2009).

A recent study (Lagas *et al*, 2008) shed some light on significant part of salinomycin toxicity. They reported that salinomycin is substrate of the efflux system of P-glycoprotein. Furthermore, their work suggested that in some animals when the P-glycoprotein is deleted or mutated the sensitivity and toxicity to ionophore increased substantially. This notion has been raised previously (Maeda and Sugiyama, 2008) and it could explain the sensitivity of the Arabian camels to salinomycin.

References

Agaoglu ZT, Akgul Y, Keles I, Ugras S, Aksoy A and Cinar A (2002). Accidental salinomycin intoxication of Angora goats in Turkey. *Small Ruminant Research* 45:159-161.

- Aleman MK, Magdesian G, Peterson TS and Galey FD (2007). Salinomycin toxicosis in horses. *Journal of American Veterinary Medical Association* 230:1822-1826
- Ayoub, MA and AA Saleh (1998). A comparative physiological study between camels and goats during water deprivation. *Proceedings of the 3rd Annual Meeting for Animal Production Under Arid Conditions* 1:71-87. United Arab Emirates University, UAE.
- Bastianell SS, Fourie N, Prozesky L, Nel PW and Kellerman TS (1995). Cardiomyopathy of ruminants induced by the litter of poultry fed on rations containing the ionophore antibiotic, maduramicin. Part II. Macropathology and histopathology. *Onderspoort. Journal of Veterinary Research* 62:5-18.
- Callaway TR, Edrington TS, Rychlik JL, Genovese KJ, Poole TL, Jung YS, Bischoff KM, Anderson RC and Nisbet DJ (2003). Ionophores: their use as ruminant growth promotants and impact on food safety. *Current Issues Intestinal Microbiology* 4:43-51.
- Dalvi RR and Sawant SG (1990). Studies on monensin toxicity in goats. *Journal of Veterinary Medicine A*. 37:352-355.
- Galitzer SJ, Ohme FW, Barley EE and Daytor AD (1986). Pathologic changes associated with experimental lasalocid and monensin toxicosis in cattle. *American Journal of Veterinary Research* 47:2624-2626.
- Goldstein RZ, Volkow ND, Wang GJ, Fowler JS, Rajaram S. (2001). Addiction changes orbitofrontal gyrus function: involvement in response inhibition. *Neuro Report* 12: 2595-2599.
- Hall JO (2001). Toxic feed constituents in the horse. *Veterinary Clinics of North America: Equine Practice Survey* 17:479-89.
- Harrison SM and Boyett MR (1995). The role of the Na^+Ca^{2+} exchanger in the rate dependent increase in contraction in guinea pig ventricular myocytes. *Journal of Physiology* 482:555-566.
- Johansen CH, Bjerrum L and Pedersen K (2007). Impact of salinomycin on the intestinal microflora of broiler chickens. *Acta Veterinaria Scandinavica* 26:49-30.
- Klappe K, Hummel I, Hoekstra D and Kok JW (2009). Lipid dependence of ABC transporter localization and function. *Chemistry and Physics of Lipids* 161:57-64.
- Lagas Jurjen S, Rolf W, Sparidans Robert AB, Van Waterschoot E I, Wagenaar Jos H Beijnen, and Alfred H Schinkel (2008). P-Glycoprotein Limits Oral Availability, Brain Penetration, and Toxicity of an Anionic Drug, the Antibiotic Salinomycin. *Antimicrobial Agents and Chemotherapy* 52:1034-1039.
- Maeda K and Sugiyama Y (2008). Impact of genetic polymorphisms of transporters on the pharmacokinetic, pharmacodynamic and toxicological properties of anionic drugs. *Drug Metabolism and Pharmacokinetics* 23(4):223-35.
- Mousa HM and Sheikh HA (1992). Monensin poisoning in Dromedary Camels. *Dtsch. tierarztl. Wschr.* S99:464.
- Narula J, Pandey P, Arbustini E, Haider N, Narula N, Kolodgie FD, Dal Bello B, Semigran MJ, Bielsa-Masdeu A, Dec GW, Israels S, Ballester M, Virmani R, Saxena S,

- Kharbanda S (1999). "Apoptosis in heart failure: Release of cytochrome c from mitochondria and activation of caspase-3 in human cardiomyopathy." Proceedings of National Academy of Sciences, USA 96:8144-8149.
- Nation PN, Crowe SP and Harris WN (1982). Clinical signs and pathology of accidental monensin poisoning in sheep. Canadian Veterinary Journal 23:323-326.
- Newcombe M, Fitz-coy SH and Harter-Dennis JM (1992). The effect of feed restriction and eimeria maxima infection with or without medication on growth and feed intake in broilers. Poultry Science 71:1442-1449.
- Pressman CB and Fahim M (1982). Pharmacology and toxicology of the monovalent carboxylic ionophores, Annal Review of Pharmacology 22:465-90.
- Safran N, Aizenberg J and Bark H (1993). Paralytic syndrome attributed to lasalocid residues in a commercial ration fed to dogs. Journal of American Veterinary Medical Association 202:1273-1275.
- Tribulova N, Ravingerova T, Okruhhcova L, Gabaner I, Fickova M, Pancza D, Slezak J, Manoach M (2000). Modulation of myocardial cAMP level by tedisamil - a possible mechanism involved in its antifibrillatory effect Mol Cell Biochem : Mol Cell (1-2):75-80.
- Van Assen EJ (2006). A case of salinomycin intoxication in turkeys. Canadian Veterinary Journal 47:256-158.
- Van der Linde-Sipman S, Van den Ingh TSGAM, Van Nes JJ, Verhagen H, Kersten JGTM, Beynen AC and Plekkringa R (1999). Salinomycin-induced polyneuropathy in cats: Morphologic and epidemiologic data. Veterinary Pathology 36:152-156.
- Van Vleet JF and Ferrans VJ (1984). Ultrastructural alteration in the arterial myocardium of pigs with acute monensin toxicosis in cattle. American Journal of pathology. 114(3)367-79.
- Vanhalderen A, Bastianello SS, Fouri N and Zumpt IF (1993). An outbreak of narasin poisoning in swine. Journal of South African Veterinary Association 64:43-46.